**IRCBG 19122**

**Percorsi diagnostici e management prenatale della patologia degli annessi fetali**

**18/10/2019**

Aula A- IRCCS Burlo Garofolo – Via dell'Istria n. 65/1 – Trieste

**Programma:**

14:30 - 14:45 **Presentazione del corso-** G. Ricci e R. Pinzano

| **Orario** | **Titolo** |
|---|---|
| *Prima sessione:* ***PLACENTA PREVIA E VASI PREVI*** | *Discussant:* ***P. Boschian e T. Stampalija*** |
| 14:45 – 15:10 | **Diagnosi-** R. Militello |
| 15:10 – 15:35 | **Follow up e management in gravidanza -** M. Piccoli |
| 15:35 – 15:50 | **Discussione - proposta del percorso regionale** |
| *Seconda sessione:* ***ALTRE ANOMALIE DEGLI ANNESSI FETALI (inserzione velamentosa del cordone, placenta bilobata, etc)*** | *Discussant:* ***F. Pirrone e L. Driul*** |
| 15:50 – 16:10 | **Diagnosi-** M. Angelini |
| 16:10 – 16:30 | **Follow up e management in gravidanza-** F. Prefumo |
| 16:30 – 16:45 | **Discussione – proposta del percorso regionale** |
| *Terza sessione:* ***PLACENTA ACCRETA, PERCRETA ED INCRETA*** | *Discussant:* ***M. Vanin e G. Maso*** |
| 17:00 – 17:20 | **Diagnosi -** I. Fantasia |
| 17:20 – 17:40 | **Follow up e management in gravidanza -** F. Prefumo |
| 17:40 – 18:00 | **Discussione – proposta del percorso regionale** |
| *Quarta sessione:* ***ALTRE TECNOLOGIE*** | *Discussant:* ***S. Facchin e R. Pinzano*** |
| 18:00 – 18:20 | **Ruolo della RMN –** M. Gregori /F. Murru |
| 18:20 – 18:40 | **Il ruolo dell'ecografia 3D/4D –** T. Stampalija |
| 18:40 – 18:50 | **Verifica dell'apprendimento** |
| 18:50 – 19:00 | **Take home message –** R. Pinzano |

**Dr.ssa Marta Angelini ASUIUD**

**Early placental development**

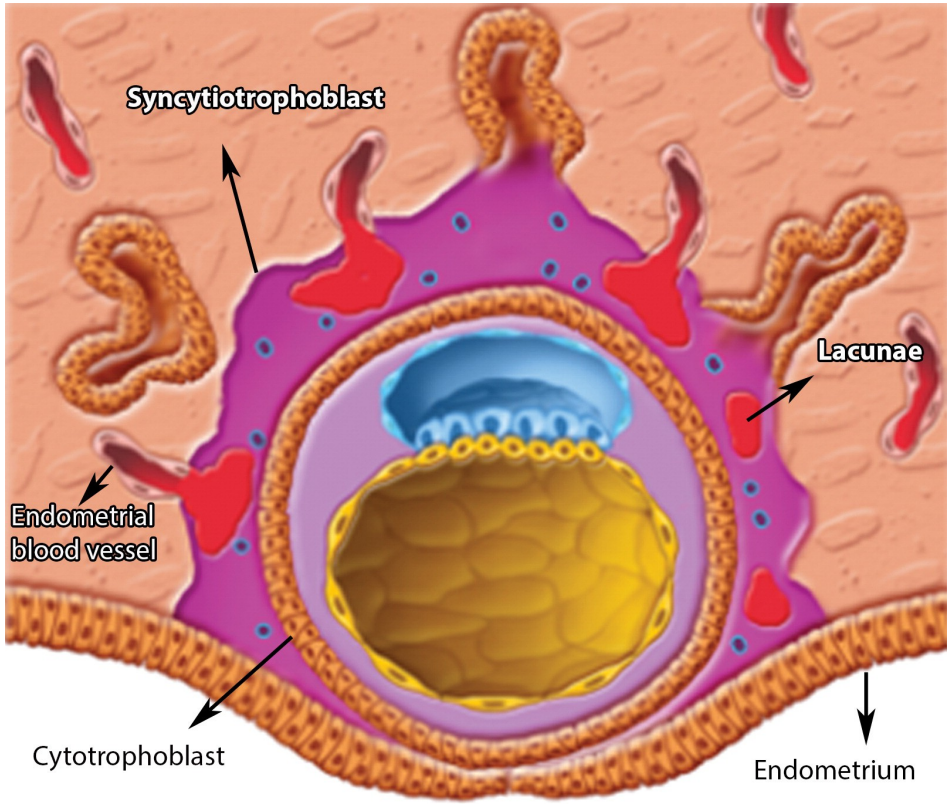


.

approximately day 7 after fertilization:

- blastocyst attaches to the endometrial epithelium at the embryonic pole of the blastocyst
- the syncytiotrophoblast cells start to penetrate and invade the endometrial connective tissue.

approximately day 9 after fertilization:

- the blastocyst implants in the endometrium.

Note the formation of extensive syncytiotrophoblasts at the embryonic pole, the start of invasion of endometrial glands, and the formation of lacunae.

Radiographics.Â 2018 Mar-Apr;38(2):642-657. doi: 10.1148/rg.2018170062.

## most common placental implantation abnormalities (PIAs)

- placenta previa (complete or incomplete)
- marginal/low-lying placenta, placenta accreta
- placentl morphology variations
- vasa previa
- velamentous cord insertion

# PIAs account for 5.6 - 8.7% of indicated preterm deliveries at <35 weeks' gestation

After **ischemic placental disease** (preeclampsia, intrauterine growth restriction, and placental abruption),

**second most common cause for indicated preterm delivery**

In symptomatic patients the timing and severity of symptomatology (ie, bleeding, labor, rupture of membranes) determines the gestational age at delivery.

Even in asymptomatic patients, preterm delivery is recommended in virtually every case to avoid maternal and/or fetal complications.

**Cesarean delivery is one of the most common of all surgical procedures, (+/- 30% USA)**

**One of the consequences of increasing cesarean delivery rates over the last few decades is an increase in PIAs.**

**This implies that we should not expect any reductions of preterm de-liveries due to PIAs in the near future.**

**It is important to focus on strategies of how to**

***improve the management of these patients.***

Vintzileos. Using ultrasound in clinical management of placental implantation abnormalities. Am J Obstet Gynecol 2015.

- increasing incidence of **artif cial reproductive tecnology pregnancy**
- increase prevalence of umbilical cord factors in IUFD
- affect the placental and umbilical cord development including
  - abnormal form of the placenta
  - velamentous cord inserion
  - vasa previa
- Prenatal diagnosis can affect the outcomes if the information is used to change the management

J.Hasegawa. **Ultrasound screening of umbilical cord abnormalities and delivery management**
Placenta 62(2018) 66-78

L Riute et al. **Incidence of and indicators for vasa previa: a sistematic review**. BJOG 123 (8))2016) 1278-1287

- increasing incidence of **artif cial reproductive tecnology pregnancy**
- increase prevalence of umbilical cord factors in IUFD
- affect the placental and umbilical cord development including
  - abnormal form of the placenta
  - velamentous cord inserion
  - vasa previa
- Prenatal diagnosis can affect the outcomes if the information is used to change the management

J.Hasegawa. **Ultrasound screening of umbilical cord abnormalities and delivery management**
Placenta 62(2018) 66-78

L Riute et al. **Incidence of and indicators for vasa previa: a sistematic review**. BJOG 123 (8))2016) 1278-1287

- **Placenta**

is a fetal organ consisting of:

- umbilical cord
- membranes (chorion and amnion)
- parenchyma

- Maternal or fetal disorders may have placental sequelae since the mother and fetus interface at this site
- Conversely, primary placental abnormalities can affect or reflect both maternal and fetal health
- **systematic assessment of the placenta is important**
- Placental and umbilical cord abnormalities are considered to account for approximately **30%** of the risk factor of intrauterine foetal death.
- The major relevant obstetric factors for cerebral palsy were almost mostly involved in placental (31%) and umbilical cord abnormalities

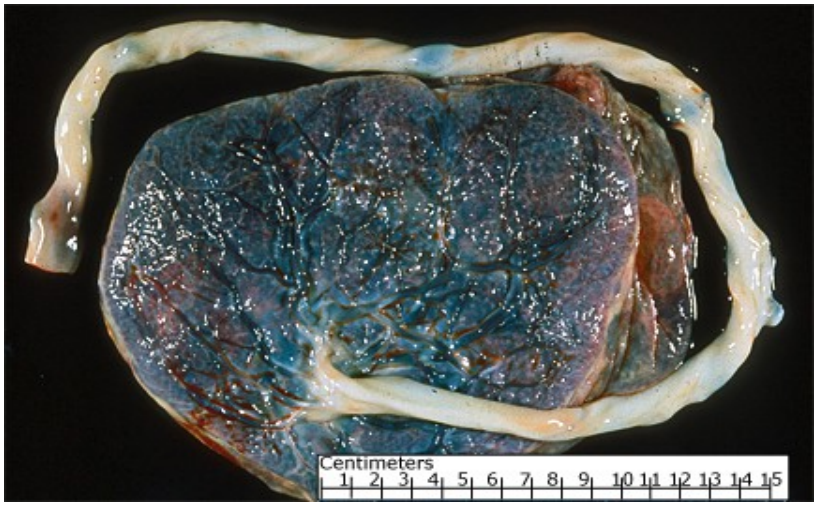


**Gross examination of the placenta**
Drucilla J Roberts, MD
Up to date
last updated: **Apr 23, 2019.**

**Placental imaging: Normal appearance with review of pathological findings.**
S. Fald et al. Radiographic.rsna.org 979-907 Vol3

**Ultrasound screening of umbilical cord abnormalities and delivery management**
J.Hasegawa. Placenta 62(2018) 66-78

# Umbilical cord

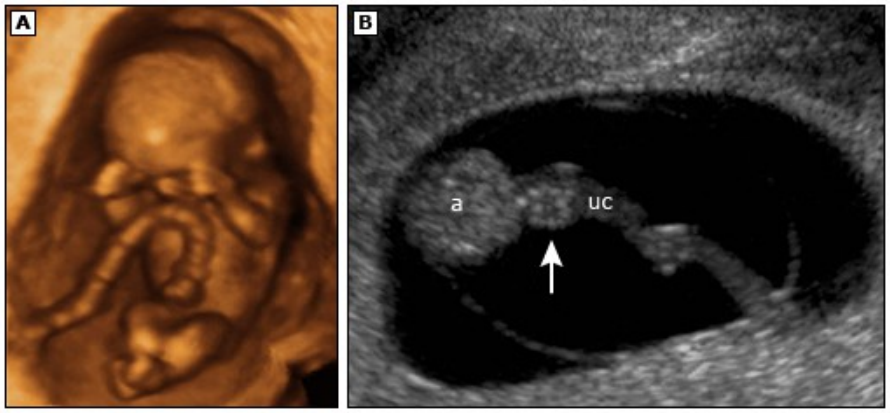


2019 UpToDate

**NORMAL ANATOMY:**

- two arteries
- one vein
- surrounded by a gelatinous stroma (ie, Wharton's jelly)
- covered by a single layer of amnion

- visualized sonographically from the eighth gestational week

first trimester,: the cord is usually coiled and approximately the same length as the crown-rump length

Determination of the number of vessels is difficult to establish by direct examination, even with color flow imaging; however, it is almost always possible to visualize the paravesical umbilical vessels with color Doppler ultrasound in the axial view of the fetal pelvis in the late first trimester.

Before the 12th gestational week, the fetal insertion often appears bulky due to normal physiological midgut herniation of intestinal loops into the cord. Herniation after 11 weeks of gestation is not normal and suggests an anterior abdominal wall defect.

**The placental insertion site can be easily identified, especially if color flow imaging is used, allowing the**

**diagnosis of marginal and velamentous insertion in early pregnancy**

Umbilical cord abnormalities: Prenatal diagnosis and management

W.Sepilveda. Up to date, feb 2019

# Umbilical cord

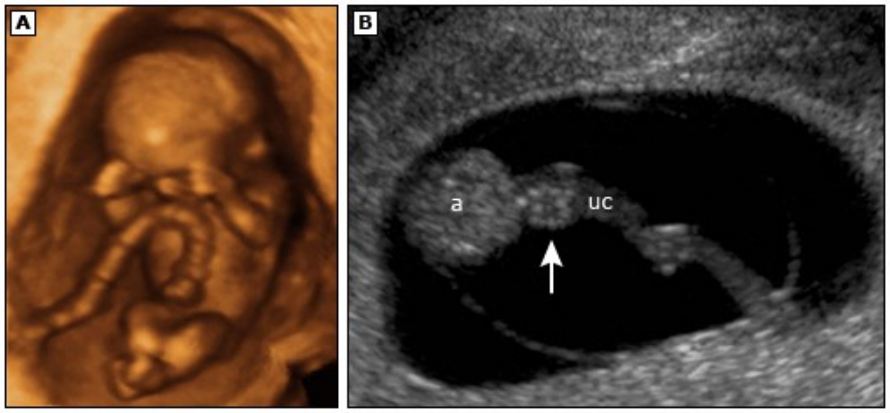


2019 UpToDate

**Coiling**

Twisting is usually to the left " barber pole"

coiling index of 0.2 (number of coils divided by length of cord examined)

genesis of cord twist : unclear

- fetal movement
- differences in the growth rates of the fetal vessels

pattern of cord coiling may be important and should be note

segmented and linked patterns more highly associated with cord occlusions due to torsion

Umbilical cord abnormalities: Prenatal diagnosis and management

W.Sepilveda. Up to date, feb 2019

Umbilical cord
**protect from**

- compression
- kinking
- stretch
- torsion
- prevent disruption of the blood supply to the fetus
- may also facilitate umbilical venous blood flow

Cords with no coiling
- poor fetal growth
- decreased activity

result from severe neural and musculoskeletal anomalies

(Several studies have reported an increased frequency of adverse pregnancy outcome, including congenital anomalies, growth restriction, fetal heart rate abnormalities, preterm birth, and intrauterine death in pregnancies with an uncoiled umbilical cord)

de Laat MW et al. Umbilcal coiling index in normal and complecated pregnancies. Obstet & Gynecol 2006; 1907-1049

hypocoiled and hypercoiled umbilical cords associate with

increased frequency of small for gestational age neonates
(15 to 16 percent versus 5 percent with normocoiled cords for both)

nonreassuring fetal heart rate patterns
(22 to 29 percent versus 11 percent)

Predanic et al. Ultrasound evaluatione of abnormal umbilical cord coiling in second trimester of gestation in association with adverse pregnancy outcome
Am J Obstet Gynecol 2015: 193-387

## Umbilical cord coiling patterns

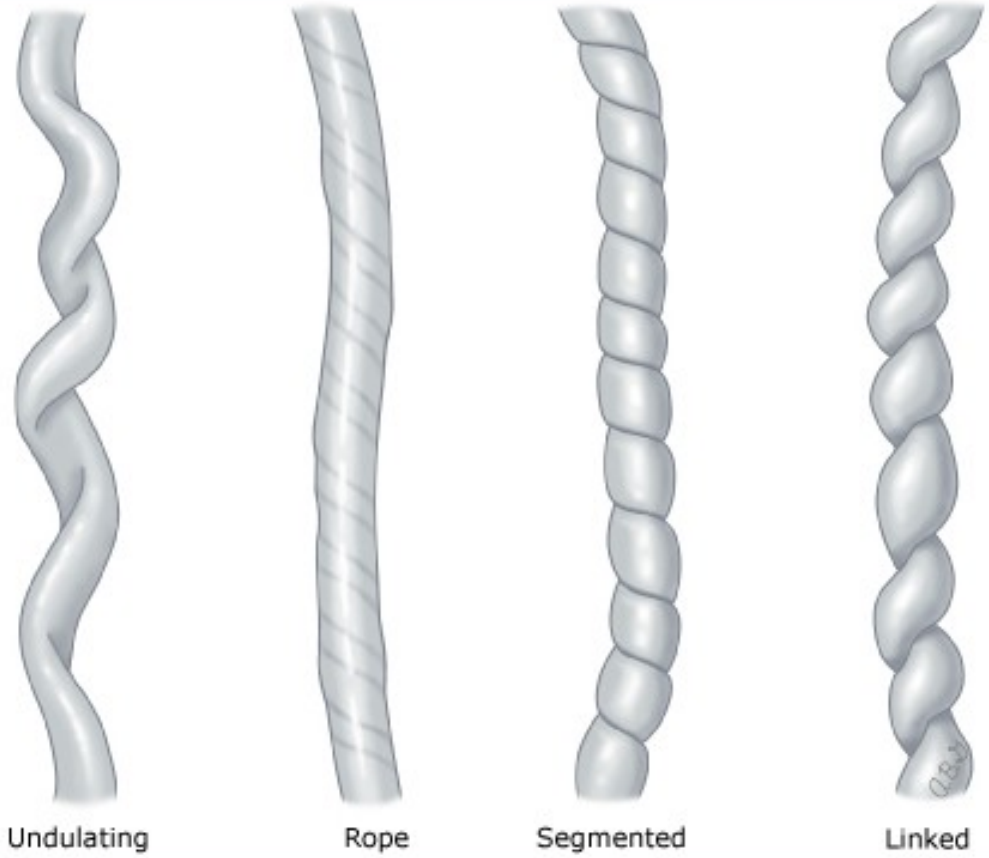


Schematic representation of the four gross umbilical cord coiling patterns.

*Modified from: Ernst LM, Minturn L, Huang MH, et al. Gross patterns of umbilical cord coiling: correlations with placental histology and stillbirth. Placenta 2013; 34:583.*

# Umbilical cord insertion

Normally :

centrally

slightly eccentrically

directly into the placental disk.

Fewer than 10 percent of insertions occur at the margin of the placenta (battledore placenta)

Abnormalities of umbilical cord insertion are more common in pregnancies resulting from

in vitro fertilizatio

multiple gestations.

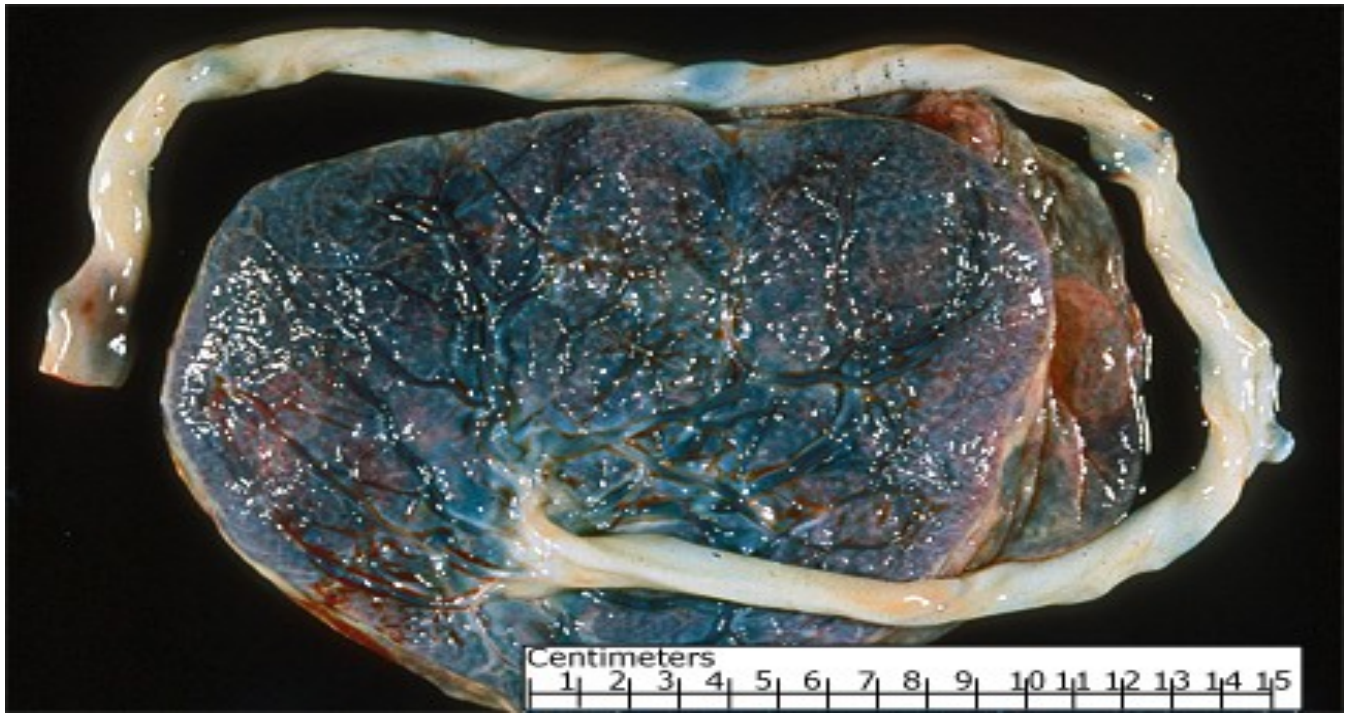

# Umbilical cord insertion

## Marginal cord insertion

placental cord insertion within 2 cm of the placental edge

prevalence of marginal cord insertion is 7%-9% in singleton pregnancies and 24-33% in twins

marginal cord insertion less than 0.5 cm from the placental edge may **progress to velamentous cord insertion** later in pregnancy

J. Hasegawa. J ObstetGynaecol Res 41:82015 1-5

J. Hasegawa. Placenta 62 (2018) 66-78

Marginal cord insertion

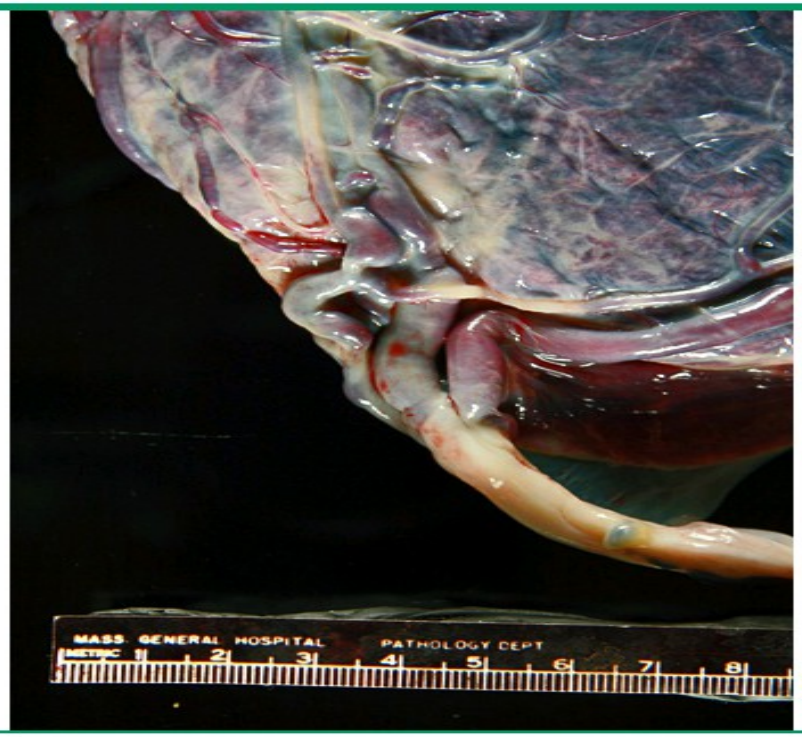


*Courtesy of Drucilla J Roberts, MD.*

UpToDate®

marginal cord insertion on birth weight and pregnancy duration in singleton pregnancy

is not associated with increased risk of growth impairment or preterm delivery.

Liu et al . J Ultrasound Med 202;21(6): 627-632

# Umbilical cord insertion

**velamentous cord insertion**

velamentous cord inserts into and traverses through the membranes (between the amnion and chorion) before entering the

placental tissue with no Wharton's jelly.

prevalence is 1% in singleton pregnancies and about 15% in monochorionic twin gestations

12% single umbilical artey

has been associated with:

- low birth weight
- abnormal intrapartum fetal heart rate pattern.

if the vessels overlie the cervix (vasa previa) they may rupture and cause fetal exsanguination.

Velamentous insertion of the umbilical cord

The placental end of the umbilical cord consists of divergent umbilical vessels surrounded only by fetal membranes, with no Wharton's jelly.
Courtesy of Drucilla J Roberts, MD.

J. Hasegawa. Placenta 62 (2018) 66-78

# Umbilical cord insertion

**velamentous cord insertion**

velamentous cord inserts into and traverses through the membranes (between the amnion and chorion) before entering the

placental tissue with no Wharton's jelly.

prevalence is 1% in singleton pregnancies and about 15% in monochorionic twin gestations

12% single umbilical artey

has been associated with:

- low birth weight
- abnormal intrapartum fetal heart rate pattern.

if the vessels overlie the cervix (vasa previa) they may rupture and cause fetal exsanguination.

Velamentous insertion of the umbilical cord

The placental end of the umbilical cord consists of divergent umbilical vessels surrounded only by fetal membranes, with no Wharton's jelly.
Courtesy of Drucilla J Roberts, MD.

J. Hasegawa. Placenta 62 (2018) 66-78

## velamentous cord insertion

this condition has been associated with:

**increased preterm birth rate** by approximately 2-fold:

- small-for-gestational-age infants,
- placental abruption,
- vasa previa
- nonreassuring fetal status

increased rates of

emergent cesarean delivery,

low Apgar scores,

admission to neonatal intensive care unit,

fetal and perinatal death.

Velamentous insertion of the umbilical cord

The placental end of the umbilical cord consists of divergent umbilical vessels surrounded only by fetal membranes, with no Wharton's jelly.
Courtesy of Drucilla J Roberts, MD.

UpToDate®

C J Lockwoodet al

Up to date Mar 2019

**Ultrasonographically**:

## velamentous cord insertion

Umbilical cord sheat end several centimeters from the placenta

Umbilical vessels separate from each other and cross between the membranes

Umbilical vessels enter the placenta margin parallel to the uterine wall, and connect to the superficial placental vessels

The umbilical vessels diverge as they traverse the membrane

They remain immobile when the uterus is shaken by the ultrasonographer in cointrast, a loop of umbilical cord will move when the uterus is shaken

Visualisation of the placental cord insertion site becomes more difficult with advancing gestation

It should be evaluated in the second trimester

**Ultrasound image of velamentous umbilical cord**

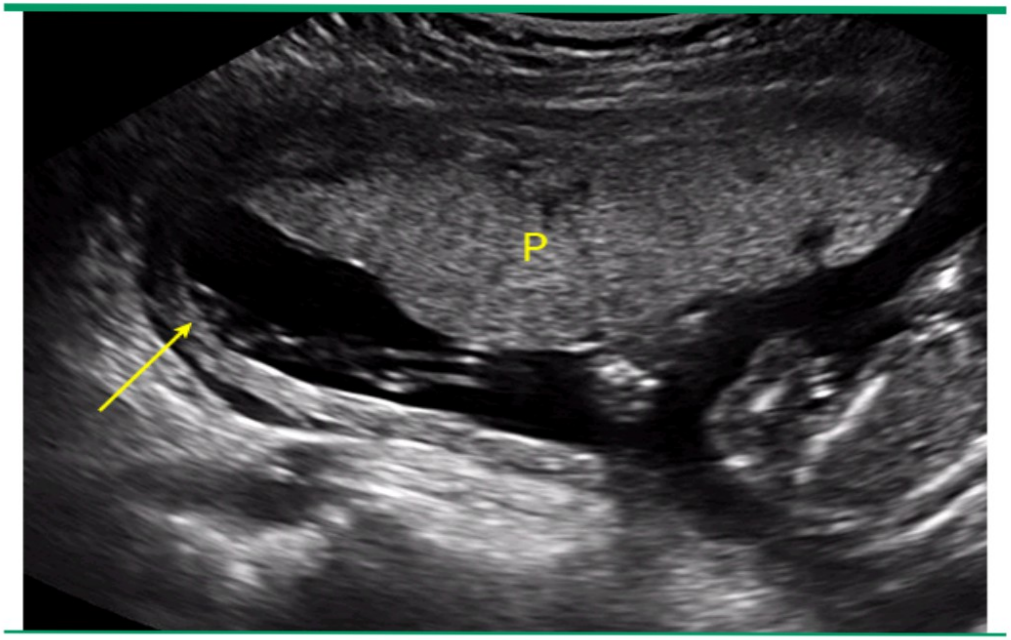


Grey scale image of umbilical cord (arrow) inserting into the fetal membranes, away from the placenta (P).
*Courtesy of Deborah Levine, MD.*

J. Hasegawa. Placenta 62 (2018) 66-78

C J Lockwoodet al

Up to date Mar 2019

## velamentous cord insertion

When abnormal umbilical cord insertion is found, additional abdominal and transvaginal colour doppler sonography is recommended to detect vasa previa and lower velamentous cord insertion

Approximately 90 % of women with vasa previa have velamentous cord insertion and 3-4% of women with velamentous cord insertion have vasa previa

Doppler enhance identification of the vessels

Diagnostic

sensitivities of 69 to 100 percent

specificities of 95 to 100 percent

**Color Doppler image of velamentous umbilical cord**

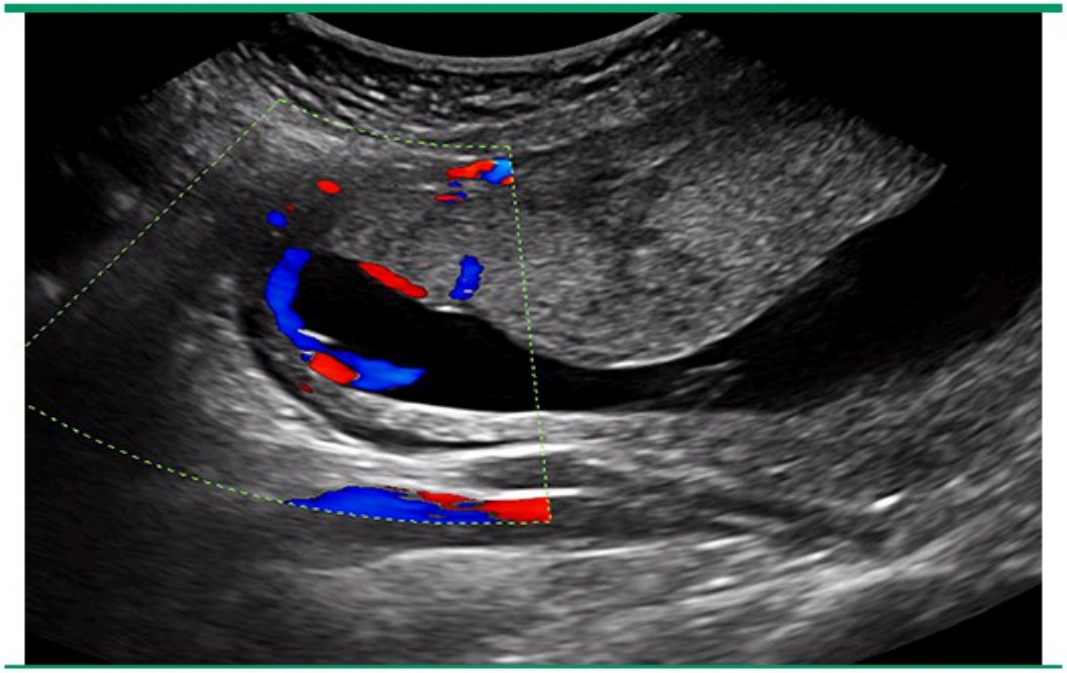

Color Doppler shows flow in the umbilical vessels separate from the cord and extending to the placenta.
*Courtesy of Deborah Levine, MD.*

UpToDate®

Monteagudo A et al. Ultrasound Obstet Gynecol 2000; 16:498

A. Vintzileos et al- American J Obstet & Gynecodoi.org/10.1016/j.ajog.2015.05.059l

## velamentous cord insertion

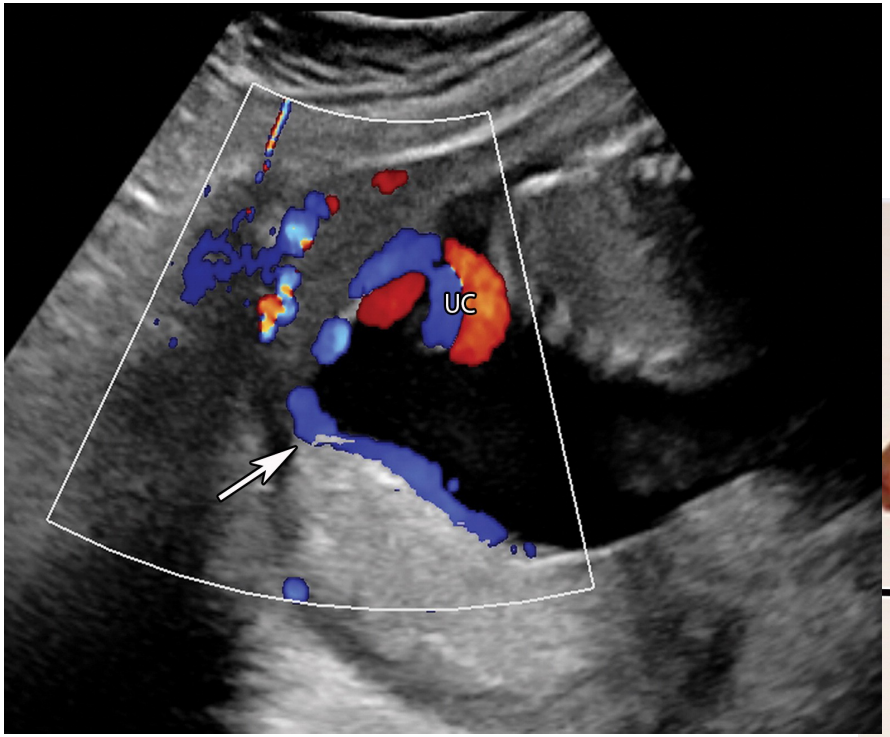


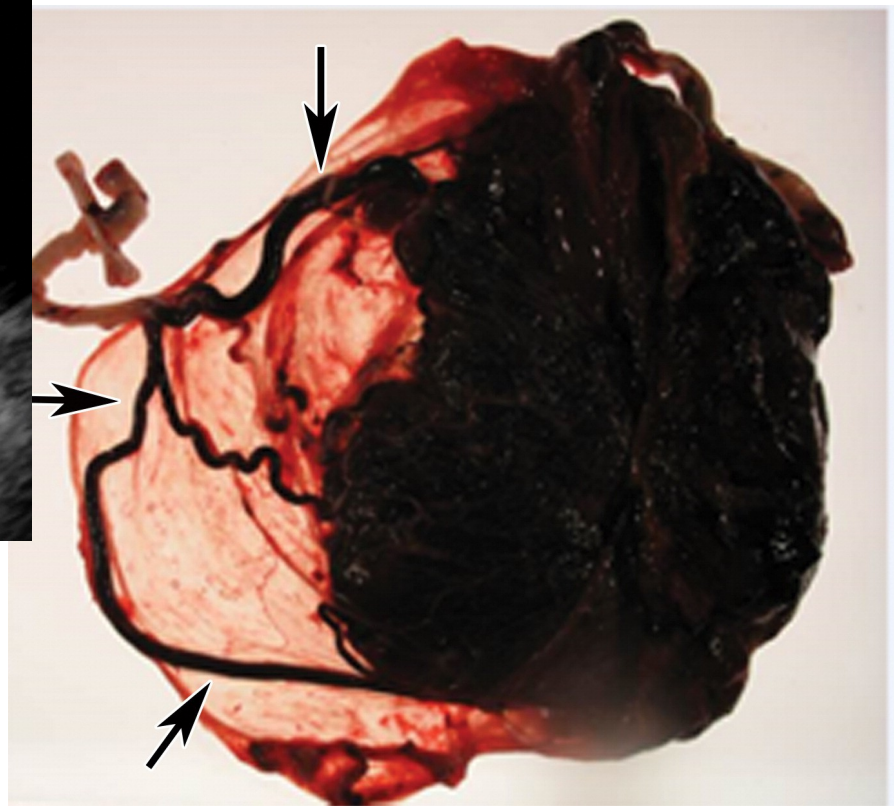

Longitudinal color Doppler image shows a velamentous cord origin. Instead of the umbilical cord *(UC)* inserting into the main placental mass, color flow confirms subtle insertion into the amnion/chorion before insertion into the margin of the placenta (arrow).

**(b)** Backlit photograph of a delivered placenta from another patient shows the cord vessels (arrows) traveling between the membranes..

Placental Imaging: Normal Appearance with Review of Pathologic Findings

RadioGraphics 2017; 37:979-998

# Placenta

**Usually**:

- discoid shape
- uniform echotexture and thickness

identified as:

6 weeks transvaginally ultrasound

10 weeks transabdominal ultrasound as a focal thickening of the hyperechoic rim of tissue surrounding the gestational sac and distinct from the myometrium

Succenturiate

Bilobate

Circumvallate

Membranacea

**Shape variant**:

etio: selective growth of some parts and loss of others

thi process, refferred to **trophoblastic trophotropism,** is thought to reflect placental growth where adequate decidua and vascular supply are present and atrophy in less favorable locations.

J P Keanne et al, Cyrr Prbl Diagn Radiol 238-255

# succenturiate placenta

# Placenta

3-6% pregnancies

separate lobule

**not contiguous** with the main placental body

This condition can predispose

the pregnancy to rupture of the bridging vessels (which

run in between the lobules) or postpartum hemorrhage secondary to a

retained lobule

When acessory lobe is smaller, velamentous vessels traverse the

membranes from the main disk to the succenturiate lobe.

It's important to **identify the comunicating vessels** to ensure the they

do not cross the cervical os (vasa previa)

Placenta with accessory lobe


Placenta succenturiata refers to a placenta with an additional lobe (arrow) of placental tissue located a few centimeters away. A placental artery and vein are within the membrane and extend from the main placental mass to the accessory lobe.

*Courtesy of Drucilla J Roberts, MD.*

UpToDa

J P Keanne et al, Cyrr Prbl Diagn Radiol 238-255

# succenturiate placenta

Placenta succenturiata.

- anterior and posterior placental disc

  colour doppler supply (atipical intramembranous vessel from main placenta )

  no placental tissue  bridging the two placental components

  careful evaluation for vasa previa or velamentous cord insertion

**Succenturiate lobe of placenta with vessel anomaly: a case report of prenatal diagnosis and literature review**

https://doi.org/10.1016/j.clinimag.2014.01.018

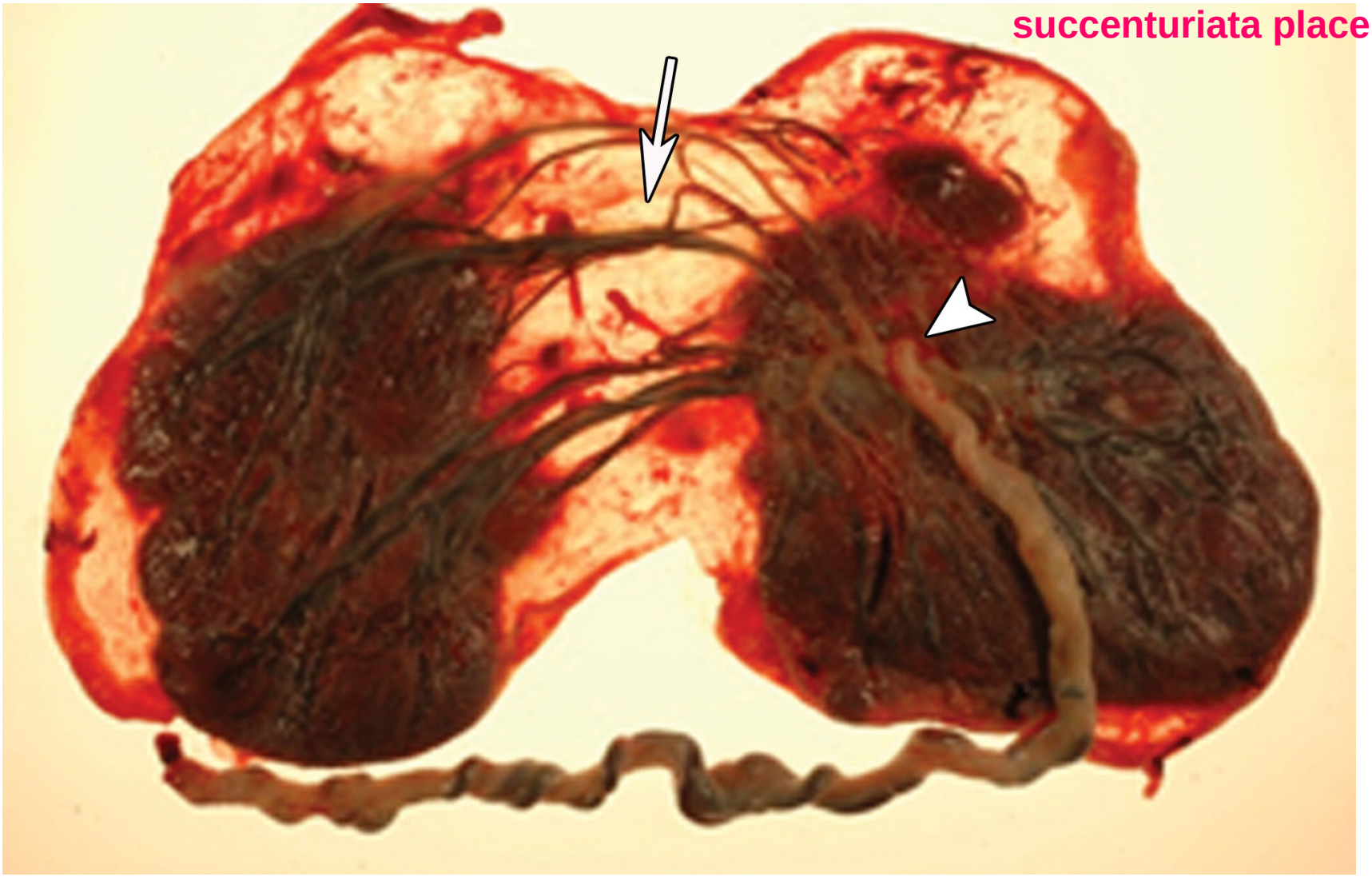


Succenturiate placental lobe. image of a placenta at 24 weeks gestation shows two separate placental lobes, with the placental cord insertion *(CI)* at the margin of the main lobe *(P)*, near the membranes connecting the lobes. The blood vessels (arrow) are seen traveling from the main lobe and crossing posteriorly toward the **succenturiate lobe** *(S)*.

Gross specimen shows two separate placental lobes interconnected by a membrane, with the blood vessels traversing the membranes (arrow). Note t**he cord origin from the main placental lobe (**arrowhead).

Radiographics.Â 2018 Mar-Apr;38(2):642-657. doi: 10.1148/rg.2018170062.

# bilobata placenta

Placenta bilobata

complete separation of the placenta into two lobes with **separate umbilical arteries and veins that unite in a single umbilical cord**. .

The **incomplete parenchymal separation typically occurs in the area of the cord insertion site,** which may be very thin or absent (fenestrate placenta).

The umbilical cord of such placentas may insert into a chorionic bridge between lobes. More commonly, membranous vessels extend between lobes or from either lobe to the cord.

When the vessels are membranous (velamentous), vasa previa, compression, and thrombosis are major concerns.

**bilobata placenta**

Bilobate placenta

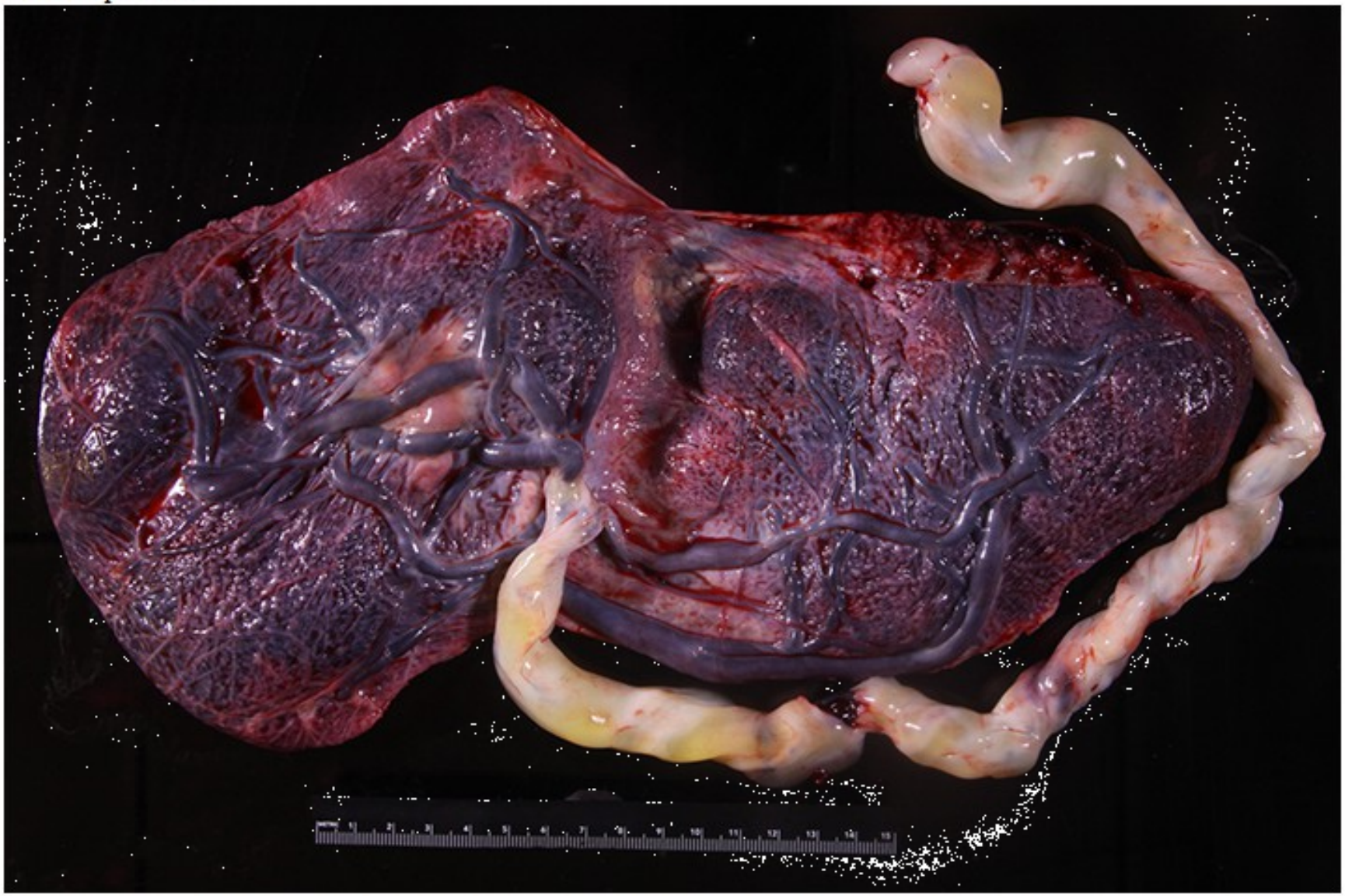

Bilobate placenta (also called bilobed or duplex placenta) with umbilical cord inserting marginally between the two lobes.
Courtesy of Drucilla J Roberts, MD.

# Placenta circumvallata

**extrachorial placenta** results from:

the size discrepance between the basal plate and the chorionic frondosum.

the chorion inserts **inward** from the usual placental margin at the basal plate - frondosum junction toward the umbilical cord, resulting in a raised annular margin

This placental edge, uncovered by a villous membrane, becomes an elevated membranous fold;

Sonography:

- identification of an infolding of the fetal membranes
- associated rim of echigenic tissue at the periphery of the placenta

Radiographics.Â 2018 Mar-Apr;38(2):642-657. doi: 10.1148/rg.2018170062.

# Placenta circumvallata

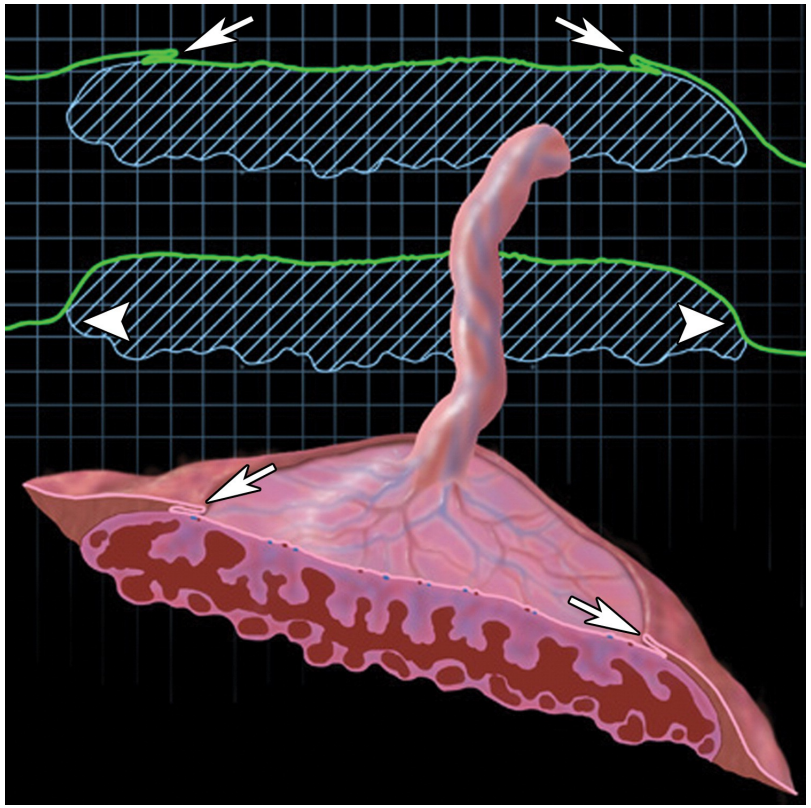

the chorion (arrows) abnormally inserting inward from the placental margin. A normal placental insertion (arrowheads) is shown for comparison.

Radiographics.Â 2018 Mar-Apr;38(2):642-657. doi: 10.1148/rg.2018170062.

# Placenta circumvallata

Prevalence : 0.2% - 21.0% of live births.

Partial circumvallate placenta, in which the membrane is lifted along part of the placenta, is 10 to 20 times more common than complete circumvallate placenta and is considered to be clinically insignificant

Complete circumvallate placenta is linked to

- higher incidence of fetal growth restriction,

- placental abruption,

- preterm birth,

- neonatal morbidity and mortality

Taniguchi H, et al. Circumvallate pla- centa: associated clinical manifestations and complications: a retrospective study. Obstet Gynecol Int 2014;2014:986230.

# Placenta circumvallata

## Diagnosis

**early part of the second trimester**

(less visible sonographically during the third trimester, because uterine enlargement causes stretching of the placenta

US findings include:

irregular lifted edge of the fetal placental attachment, within 3 cm of the placental edge

traverses parallel to the surface of the placenta and attaches to another portion of the placenta, forming a placenta-placenta ILE

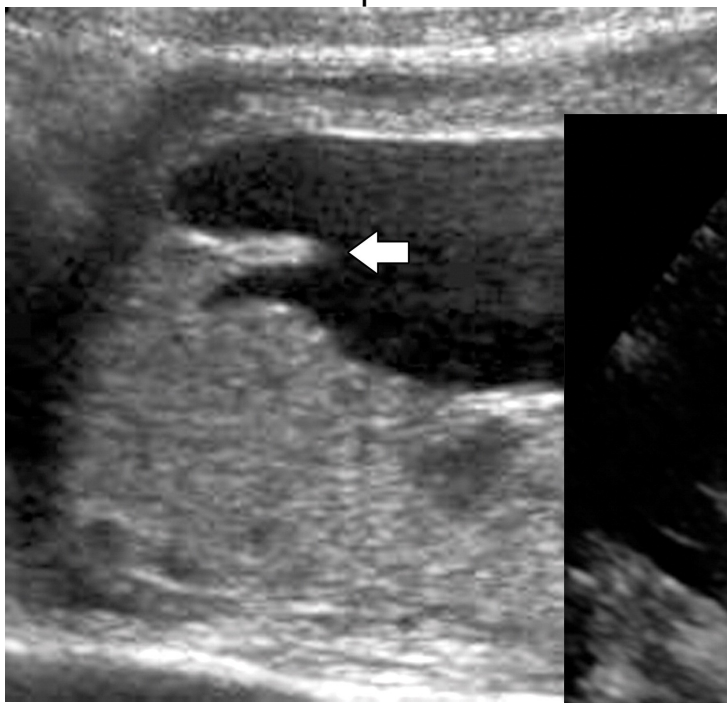

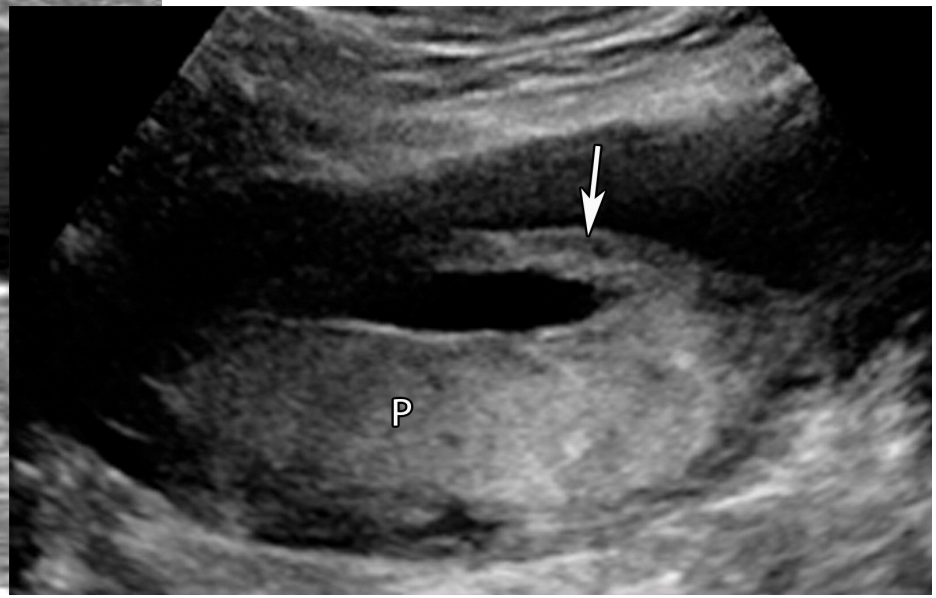


S O et al. Placental shelf: a common, typically transient and benign finding on early second-trimester sonography. Ultrasound Obstet Gynecol 2007;29(2):192–194.

Radiographics.Â 2018 Mar-Apr;38(2):642-657. doi: 10.1148/rg.2018170062.


# Placenta circumvallata

*Ultrasound in Obstetrics & Gynecology, Volume: 46, Issue: 4, Pages: 513-514, First published: 06 March 2015, DOI: (10.1002/uog.14839)*

Placental examination revealed an increased thickness with irregular anechoic areas on the periphery of the fetal surface.

color Doppler showed no blood flow within these areas. HDlive mode revealed a slightly curved placental edge

thick peripheral edges and corners in a third-trimester pregnancy;

Three-dimensional image with the HD live software of a circumvallate placenta, showing ***thick peripheral edges and curves*** (white arrow)

Three-dimensional image with HD live software of a circumvallate placenta, evidencing **thick peripheral edges and curves** (white arrow), appearance of a **tire mounted on a wheel**, .

# Placenta circumvallata


Circumvallate placenta and cord

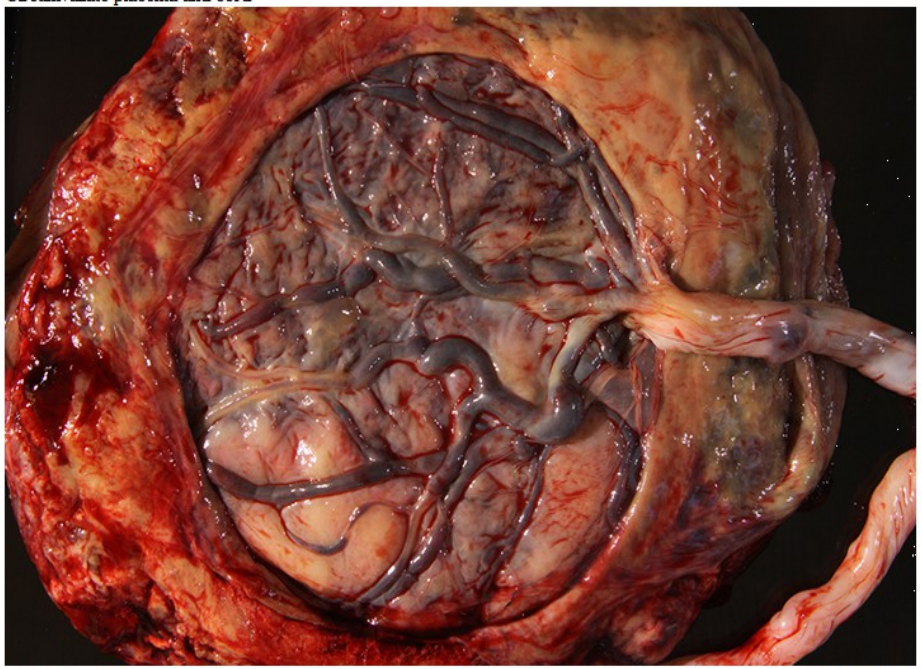

A double layer of amnion and chorion, as well as necrotic villi and fibrin, form a raised white ring around the surface of the placental disk at a variable distance from the umbilical cord insertion site; the fetal vessels do not extend beyond this ring. The extrachorionic tissue constitutes a small proportion of the placenta and usually does not compromise fetomaternal exchange.

Courtesy of Drucilla J Roberts, MD.

UpToDate®

A double layer of amnion and chorion, as well as necrotic villi and fibrin, form a raised white ring around the surface of the placental disk at a variable distance from the umbilical cord insertion site;

**the fetal vessels do not extend beyond this ring**.

The extrachorionic tissue constitutes a small proportion of the placenta and usually does not compromise fetomaternal exchange.

more prone to **premature separation and second trimester bleeding** is common.

Gross examination of the placenta

D. J. Roberts up to date feb 2019

# Placenta membranacea/diffusa

Placenta membranacea is a common  in mammalian species such as cetaceans, horses, and pigs;

**Incidence** in humans:  1 in 20.000 to 40.000 pregnancies.

**Etiopathogenesis**:

1) failure of villous atrophy in early gestation, fetal membranes remain covered by chorionic villi, and the placenta develops as a thin membranous rim of tissue in the periphery of the chorion, resulting in the terminology of placenta membranacea.

2) Vascular trophotrophism  (dynamic placentation):

the original implantation site is modified by regional variations in the decidua and maternal vascular supply. The resulting growth in areas of superior perfusion and atrophy in areas of poor perfusion lead to a distortion in placental shape

3)Others: repeated endometritis, mechanical injury to the endometrium, and endometrial hyperplasia

**Associated** with **abnormal placental adherence** in up to <u>one third of the cases</u> reported in the medical literature.

Pereira eta al Prenatal Diagnosis 2013, 33, 1293-1296

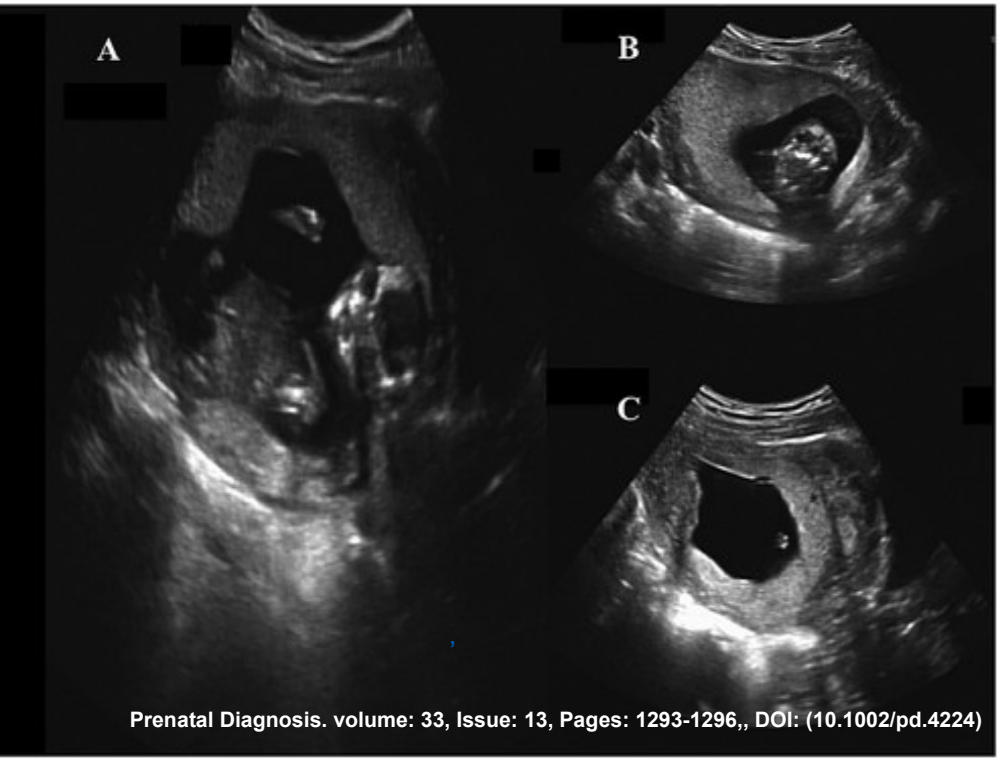


# Placenta membranacea/diffusa

## Diagnosis

fetal membranes are completely/ partially covered by villi

commonly marginal cord insertion with a distinct placental disk at the insertion site

typically vaginal bleeding in the second or third trimester.

potentially unrecognized.

Although a placenta that is uniformly distributed and maintains a reasonable thickness is easily visualized with US,

the chorionic tissue may instead be stretched thin over fetal membranes, thus evading identification.

The majority of pregnancies result in an appropriately grown preterm neonate, but outcome can range from stillbirth to a viable term delivery.

Placenta membranacea may be further complicated by postpartum hemorrhage and/or abnormal placental adherence.

Occasionally, placenta membranacea appears thicker at the cord insertion site, with placental substance progressively diminishing away from it.This is particularly important when the placental disc is fundal, as the thin distal portion of the placenta over the lower uterine segment or internal os may be missed during US surveillance Bilobate or succenturiate placental lobes may sometimes be confused with placenta membranacea; hence, they should always be considered in the differential diagnosis.

Placenta membranacea Samadh F. Ravangard â€¢ Kimberly Henderson â€¢ Kisti Fuller

Arch Gynecol Obstet (2013) 288:709â€“712 DOI 10.1007/s00404-013-2778-z

# Placenta membranacea/diffusa

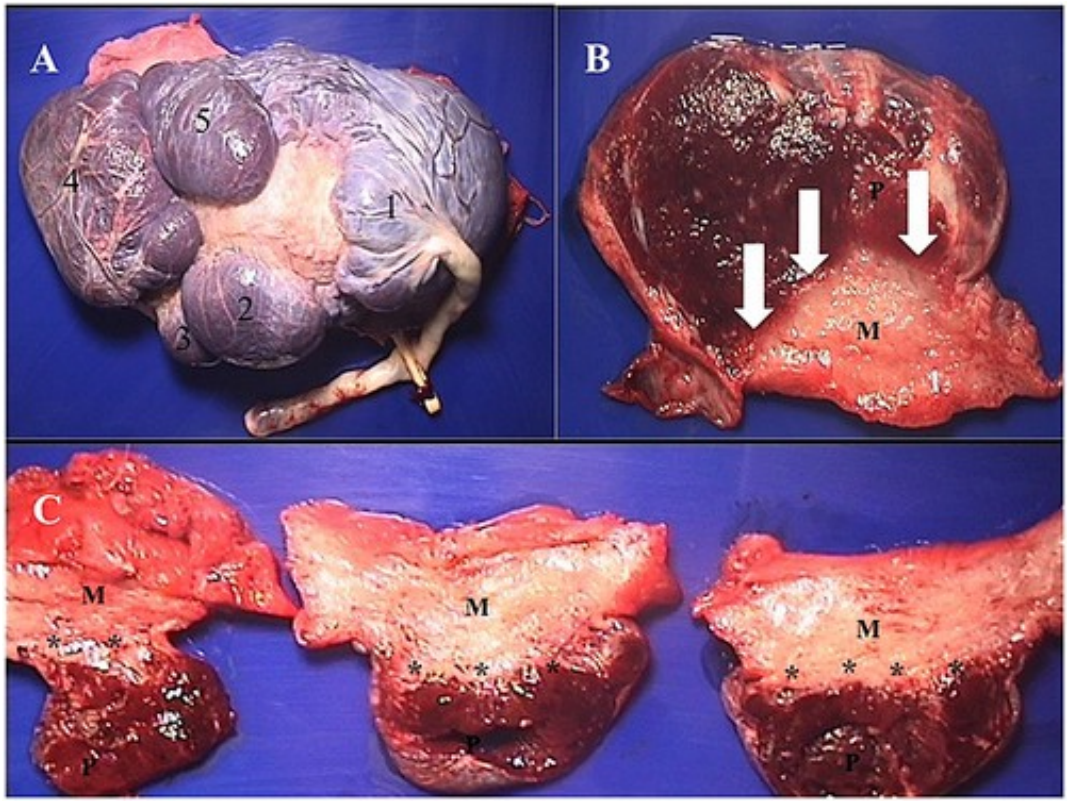


hysterectomy specimen showing a **large singleton placenta** with **5 lobe-like structures** (each numbered) **without interspersing fetal membranes**. (B) Cut surface of the posterior uterine wall showing invasion of the myometrium (M) by the placenta (P). Loss of normal myometrial-placental interface (white arrows) is also shown. (C) Cut surface of the anterior uterine wall showing a normal myometrial (M)-placental (P) interface (*)

Pereira eta al Prenatal Diagnosis 2013, 33, 1293-1296

…….PLACENTA

Anteriore.....

Posteriore.....


Fundica.....

Previa.....

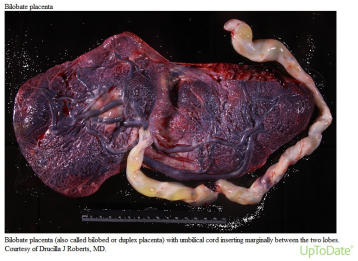


Vasa previa.....

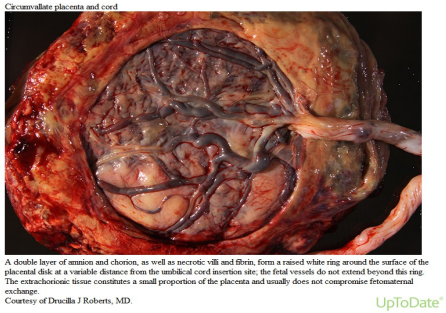


Succenturiata.....

Bilobata.....

Circumnavigata.....

……CORDONE

Prenatal diagnosis can affect the outcomes if the information is used to change the management

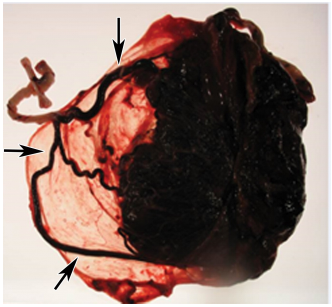

Marginale.....

Laterale.....

Velamentoso.....


Forse non solo.....e poi.....

**……grazie……**